

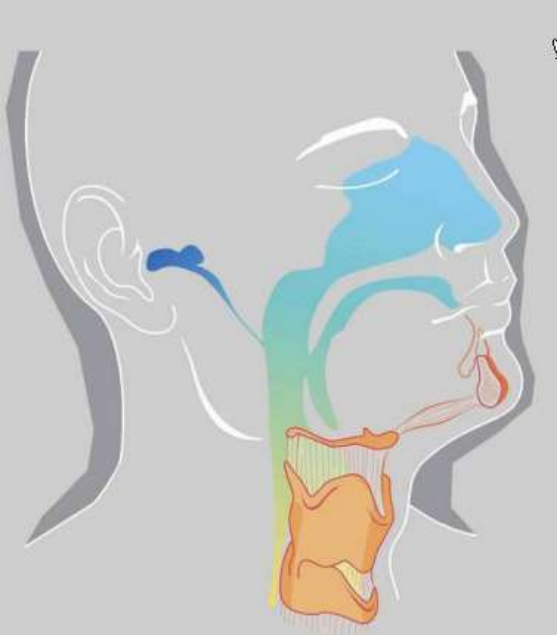


Bases da Semiologia Otorrinolaringológica

Prof. Dr. Vinicius Ribas Fonseca

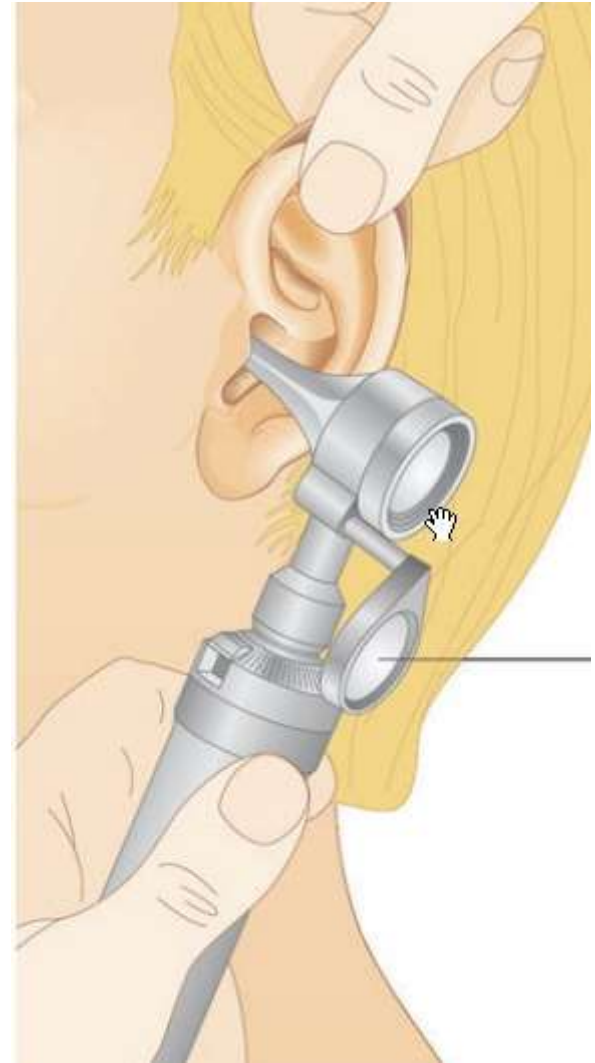
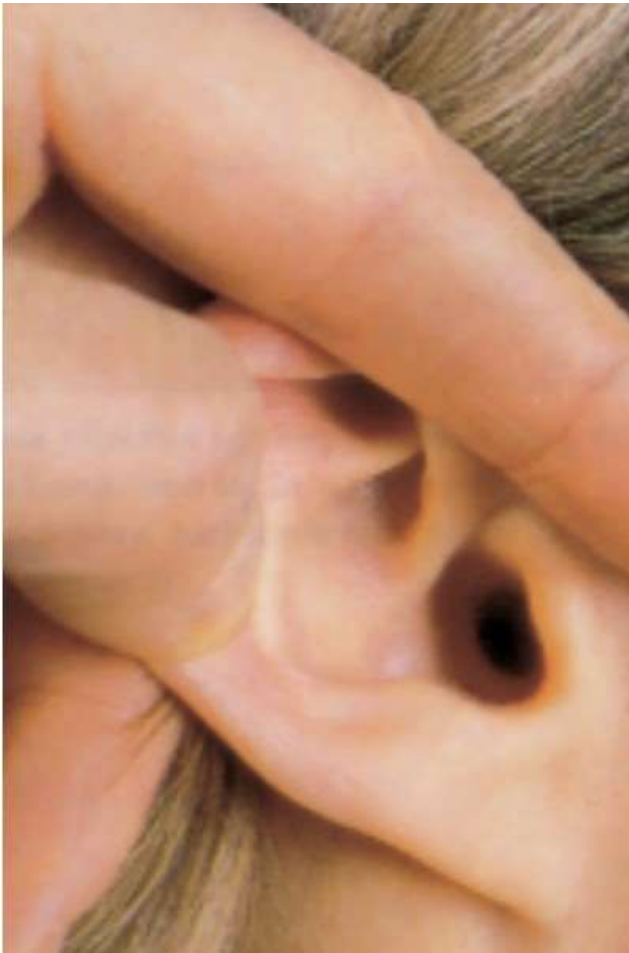

- Apresentação
 - 92230033 (cel) 91630033 (sec.)
 - vribasfonseca@gmail.com
- Apresentação do aluno
 - Nome
 - Idade
 - Cidade
 - Contato com ORL
 - Perspectiva
 - Intenção de especialidade?

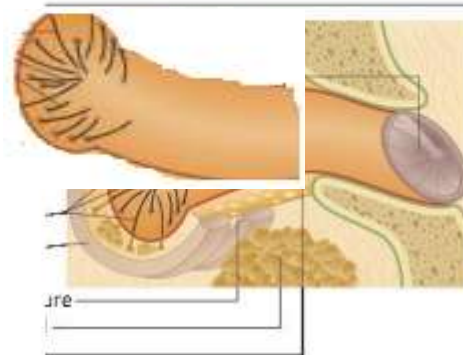
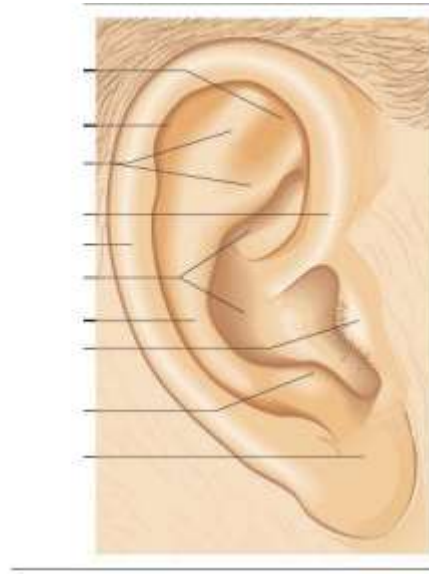

- Aulas práticas
 - Sexta feira das 13:30 até 17:30
 - Início das atividades em sala de aula
 - *Peer instruction*
 - Atendimento no ambulatório
 - Publicação da aula
 - Cirurgias
 - Materiais
 - Jaleco
 - Assistente
 - Avaliação
 - Presença
 - Participação
 - Prova de Casos clínicos

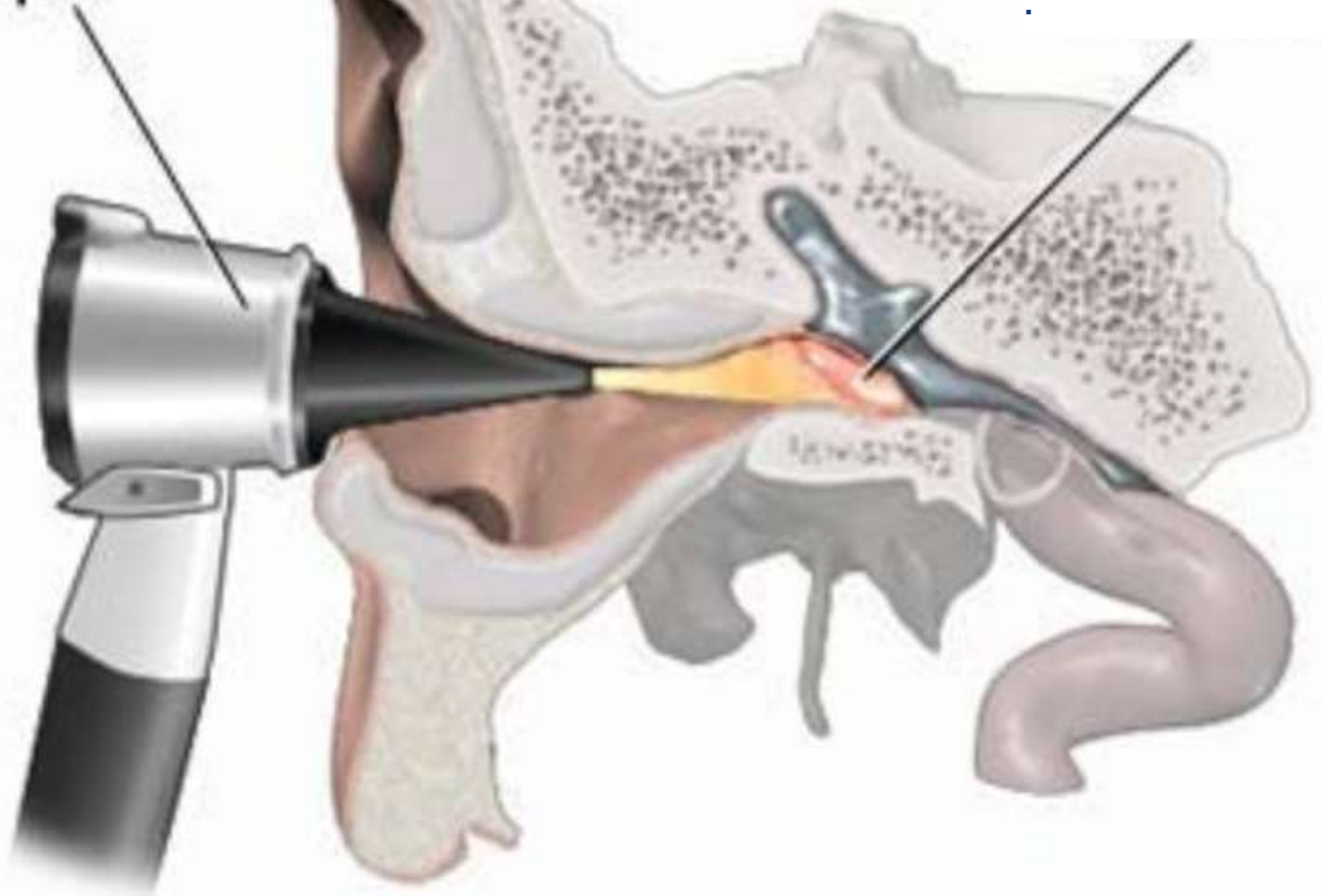
Diagnóstico de Hipoacusia:otoscopia

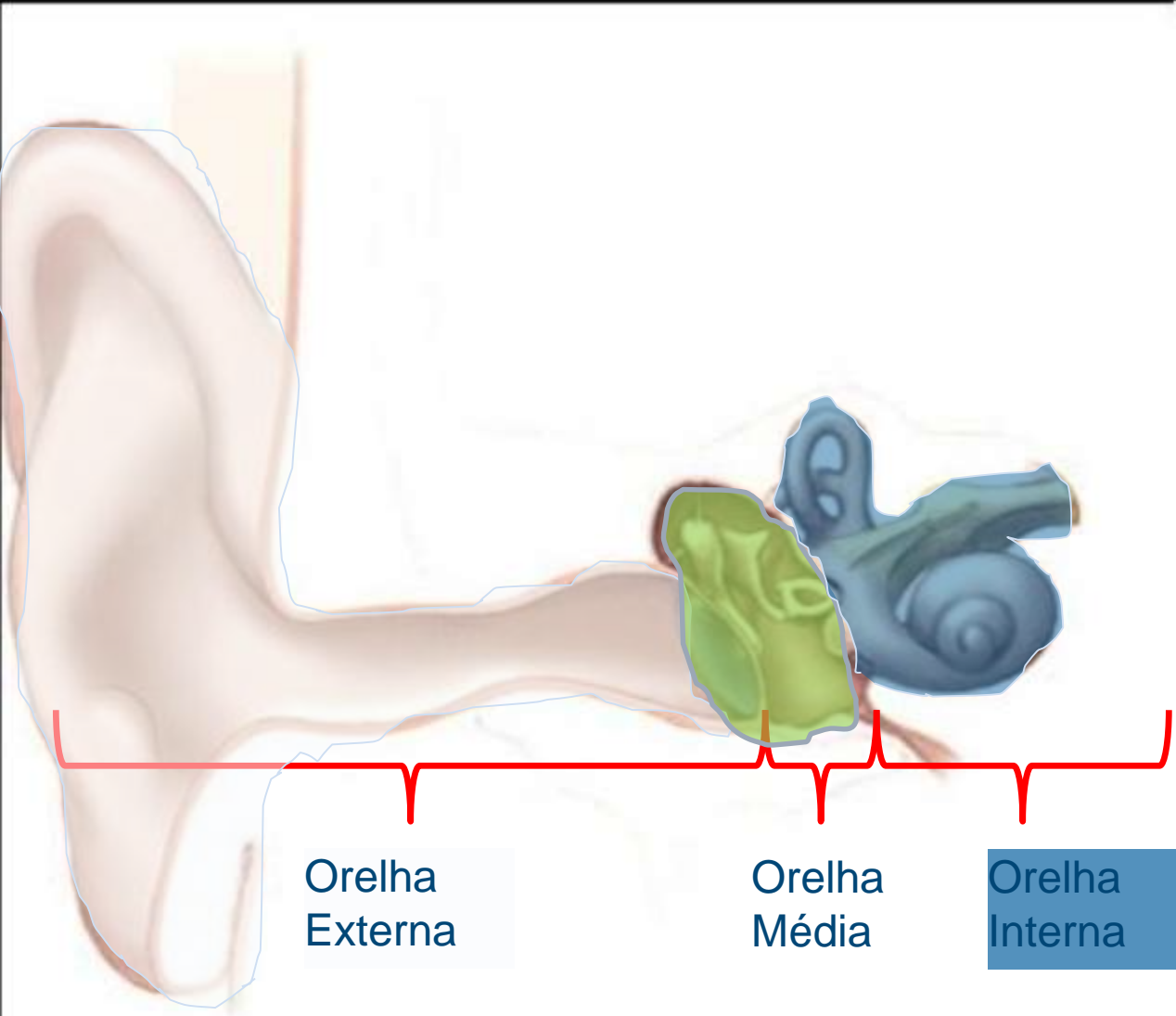


Revisão da Anatomia



Otoscopy

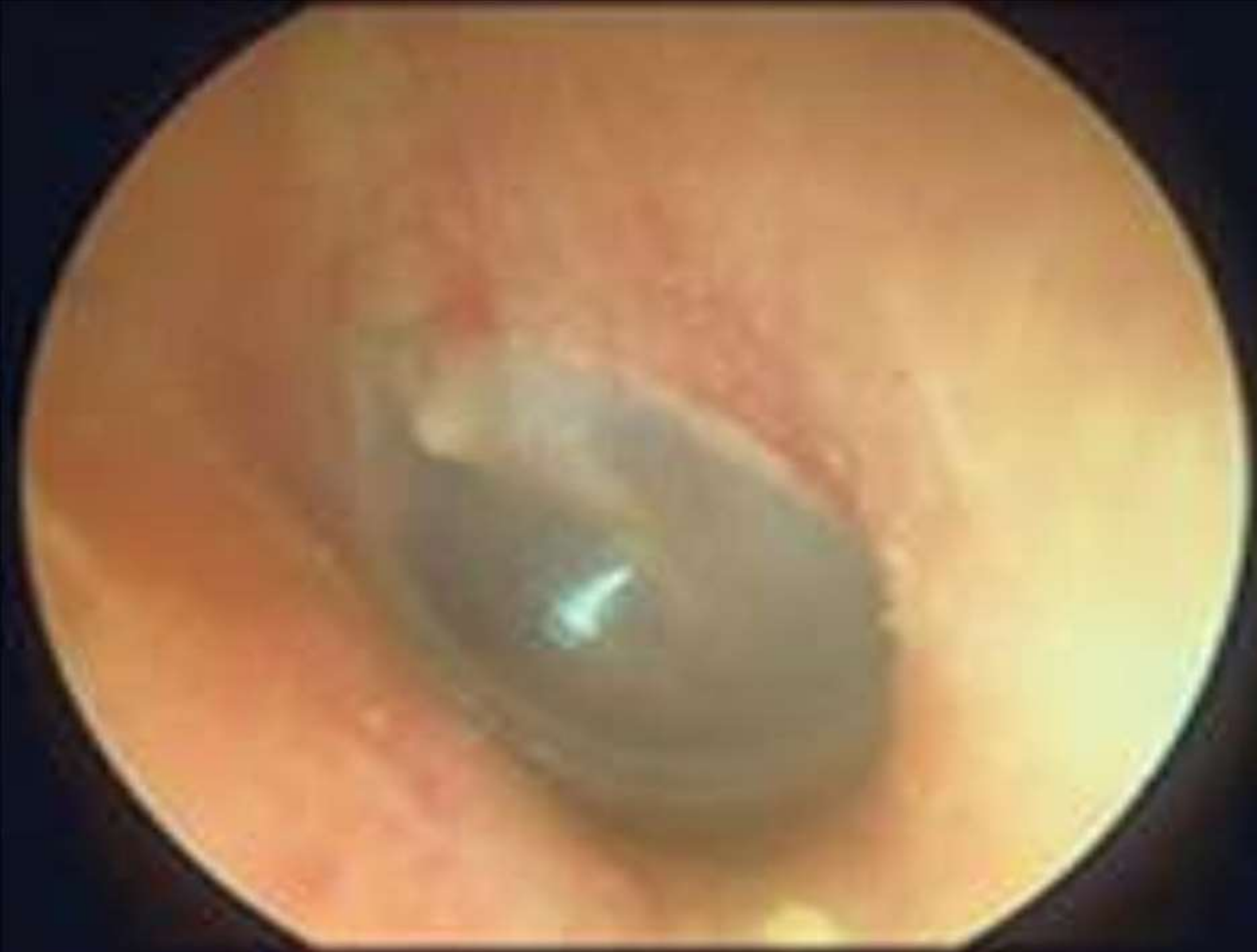



Orelha Externa

Orelha Média

Orelha Interna



TRIANGULO
LUMINOSO

SULCO
TIMPÂNICO

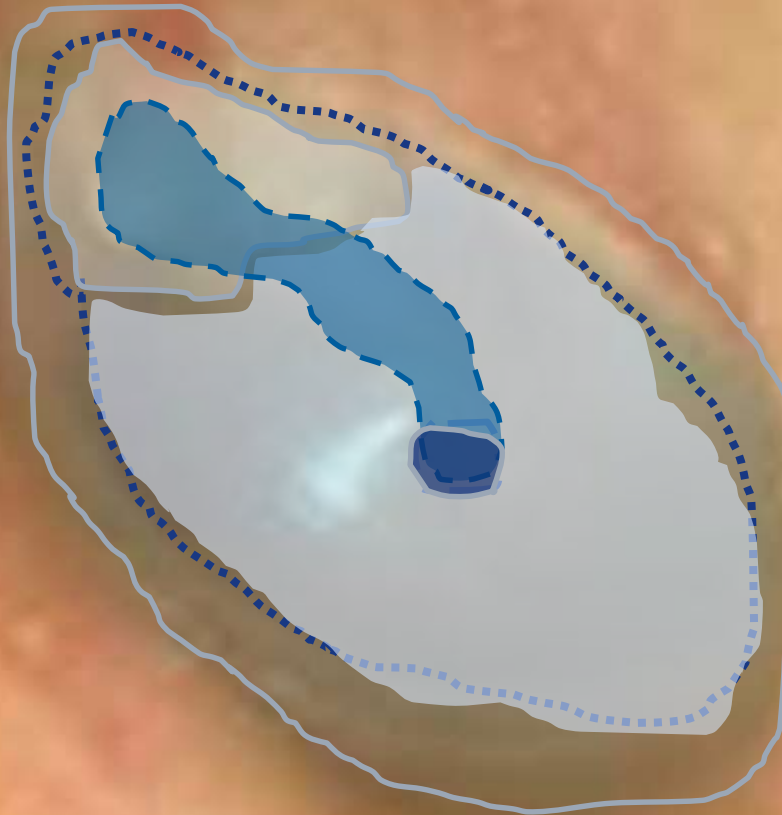ÂNULOS

PARS
FLÁCIDA

PARS TENSA

MARTELO

UMBIGO





ANTERO-
SUPERIOR

This image shows an endoscopic view of the colon, which is a large, sac-like organ in the digestive system. The view is divided into four quadrants by two dashed white lines that intersect at the center. The quadrants are labeled with text in blue boxes: ANTERO-SUPERIOR (top-left), PÓSTERO-SUPERIOR (top-right), ANTERO-INFERIOR (bottom-left), and PÓSTERO-INFERIOR (bottom-right). The mucosal lining of the colon is visible, showing a reddish-pink color with some darker spots and a slightly textured appearance. The overall lighting is somewhat dim, typical of an endoscopic procedure.

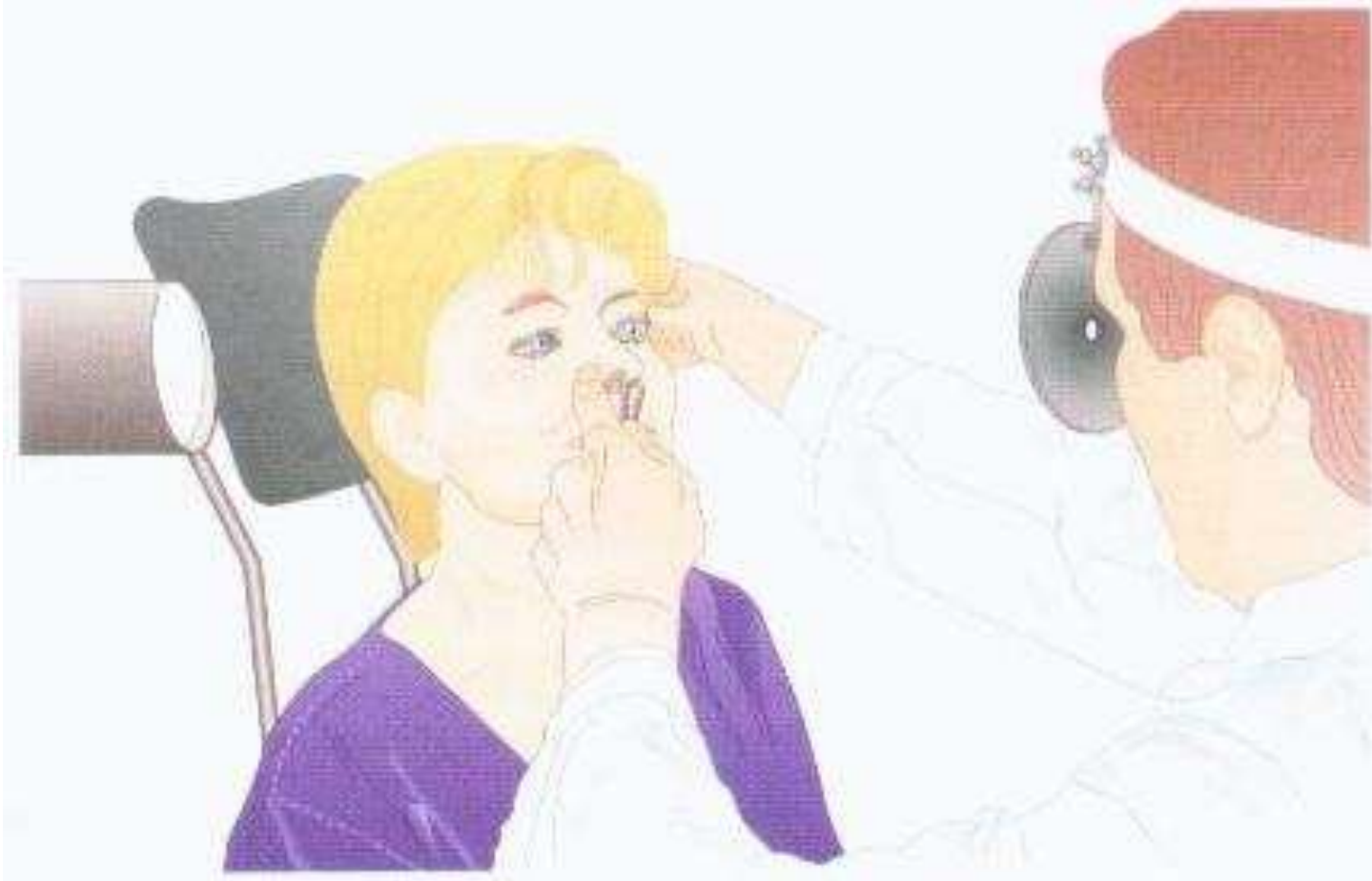
PÓSTERO-
SUPERIOR

PÓSTERO-
INFERIOR

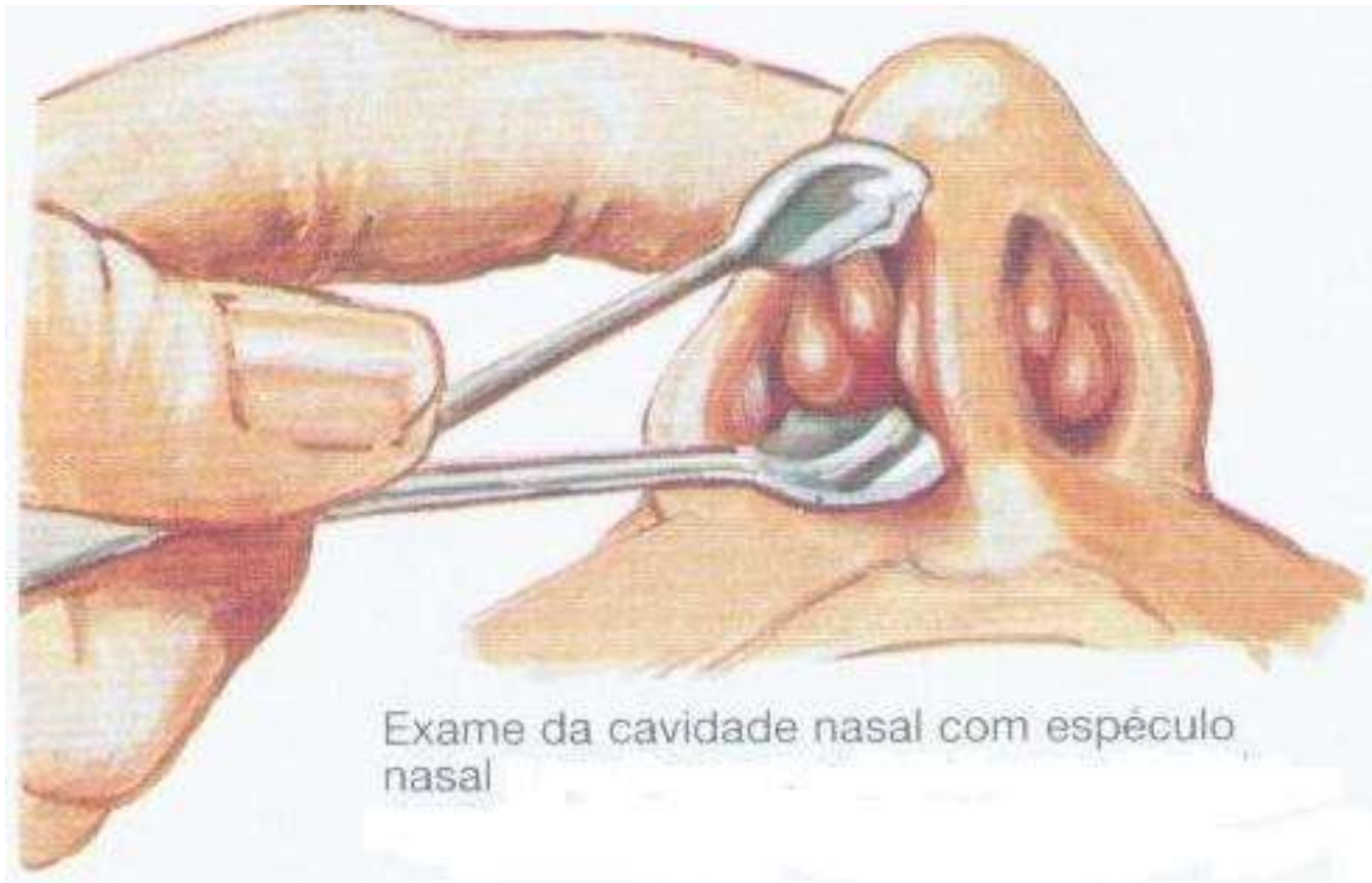ANTERO-
INFERIOR



Rinoscopia

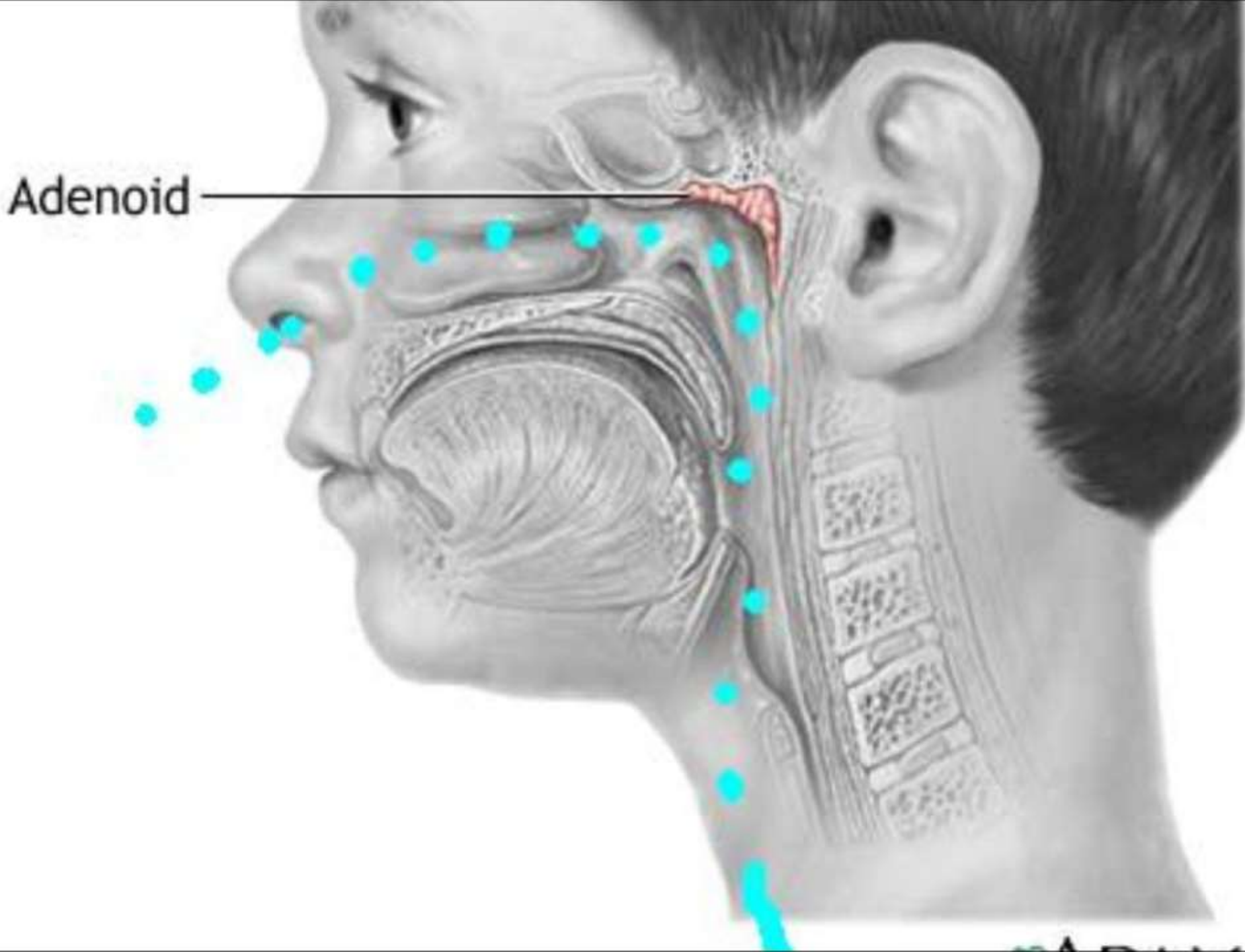


Rinoscopia



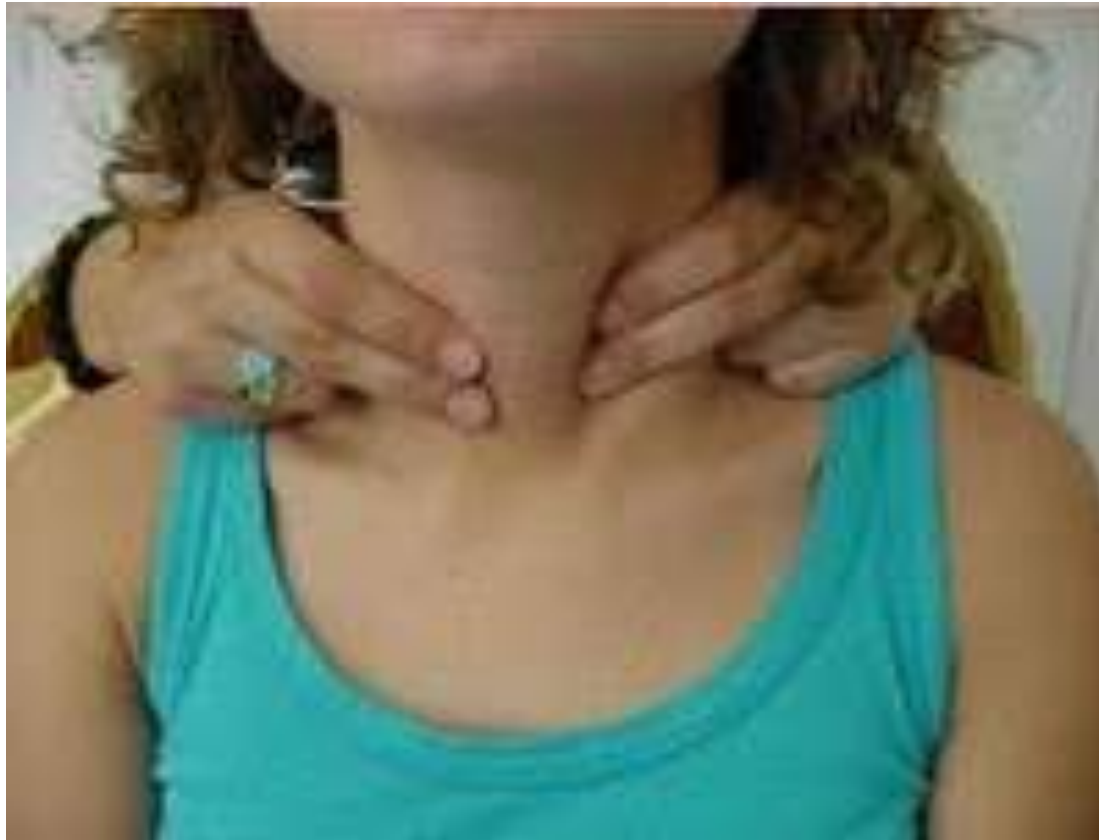Exame da cavidade nasal com espéculo nasal

Adenoid

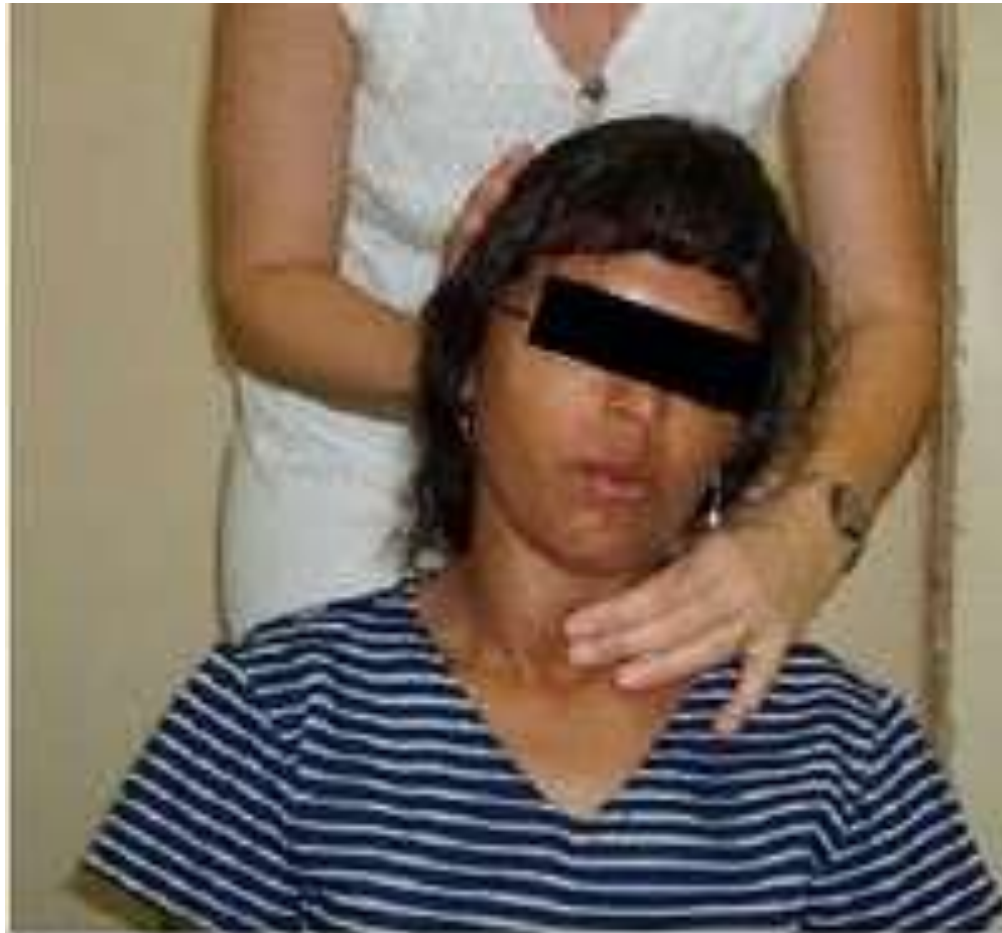



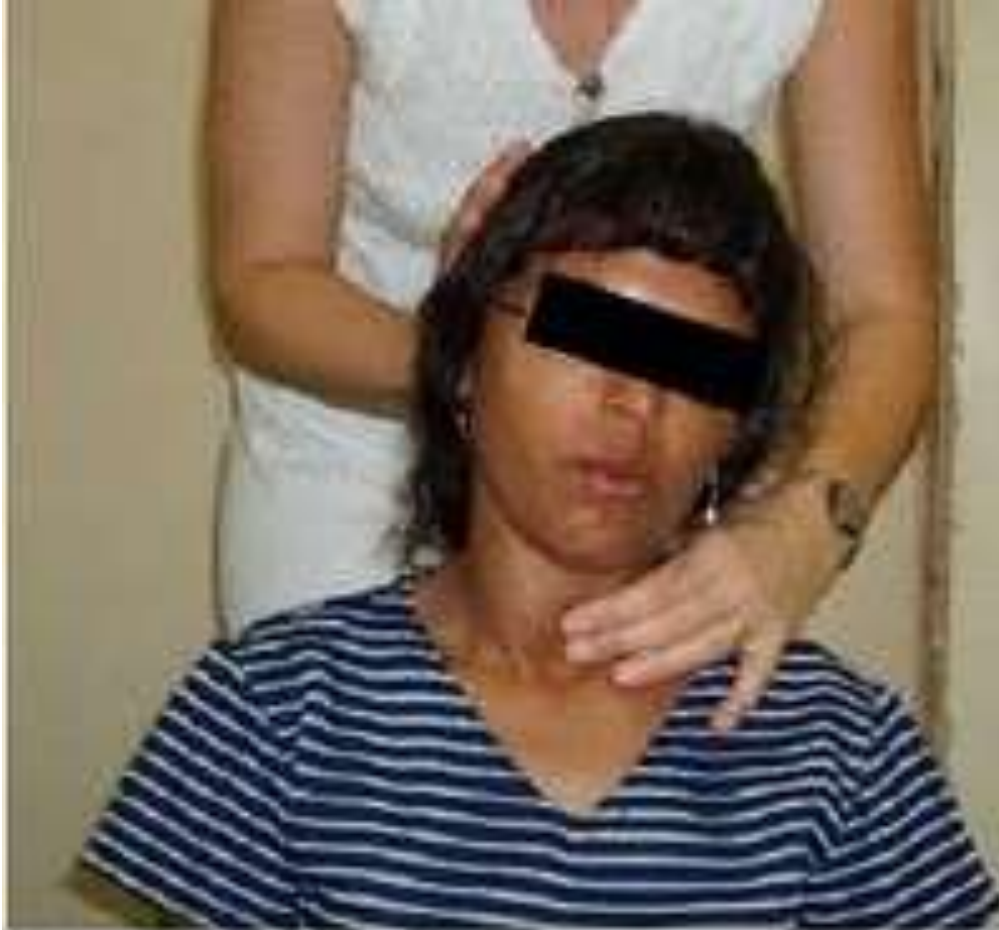Exame da Cabeça e Pescoço



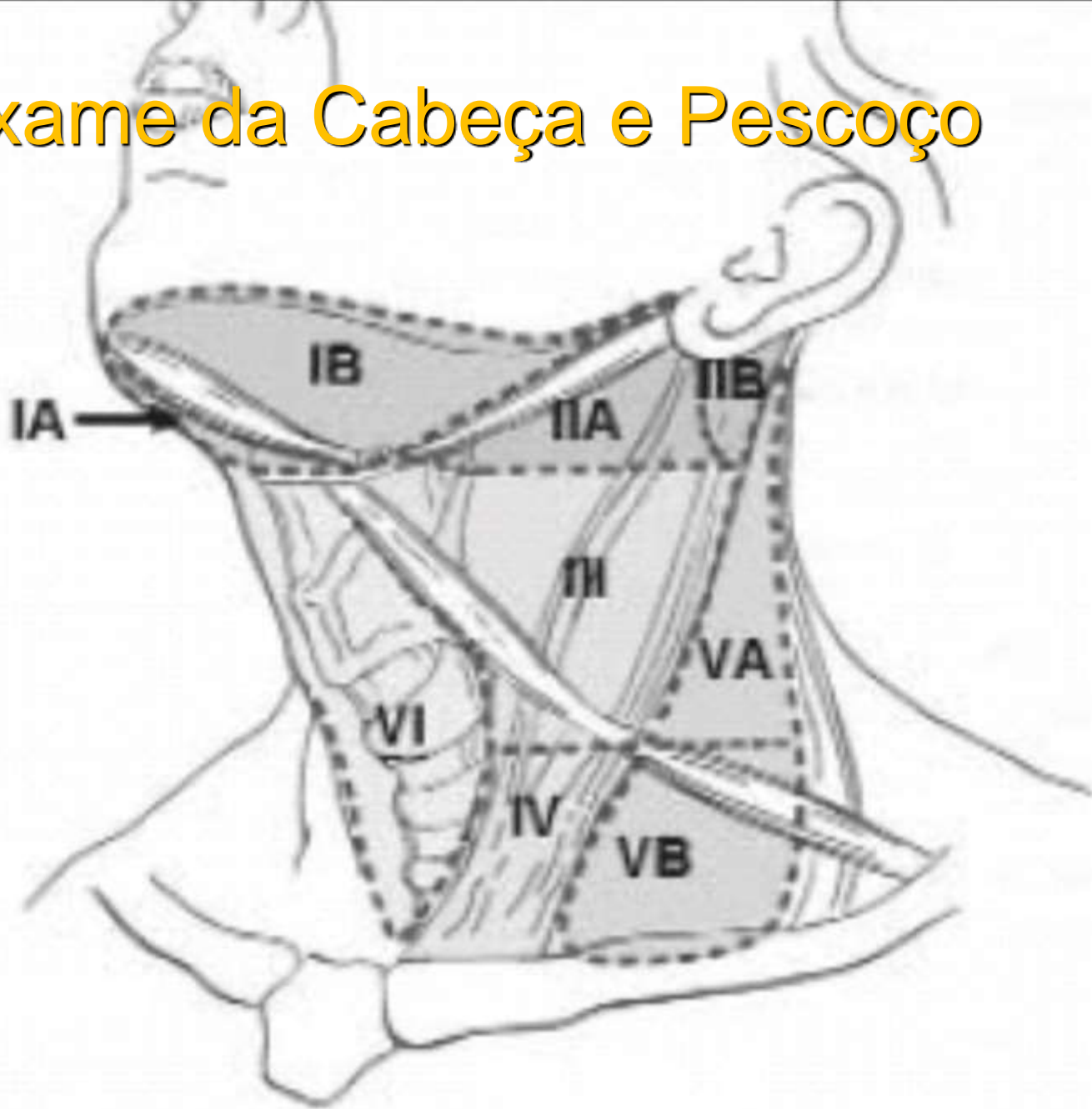
Exame da Cabeça e Pescoço



Exame da Cabeça e Pescoço



Exame da Cabeça e Pescoço

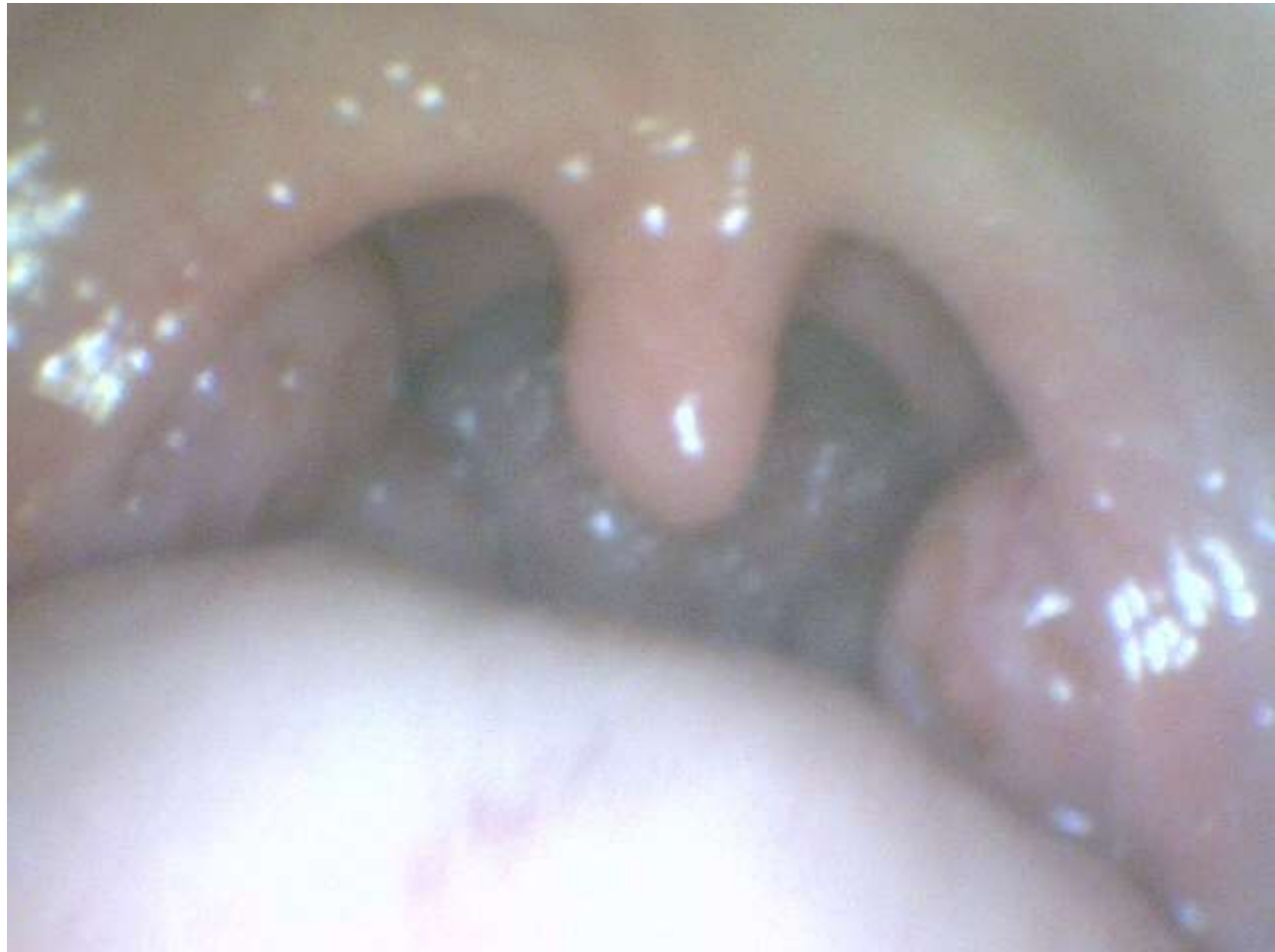

BRITTO CELEBRATION

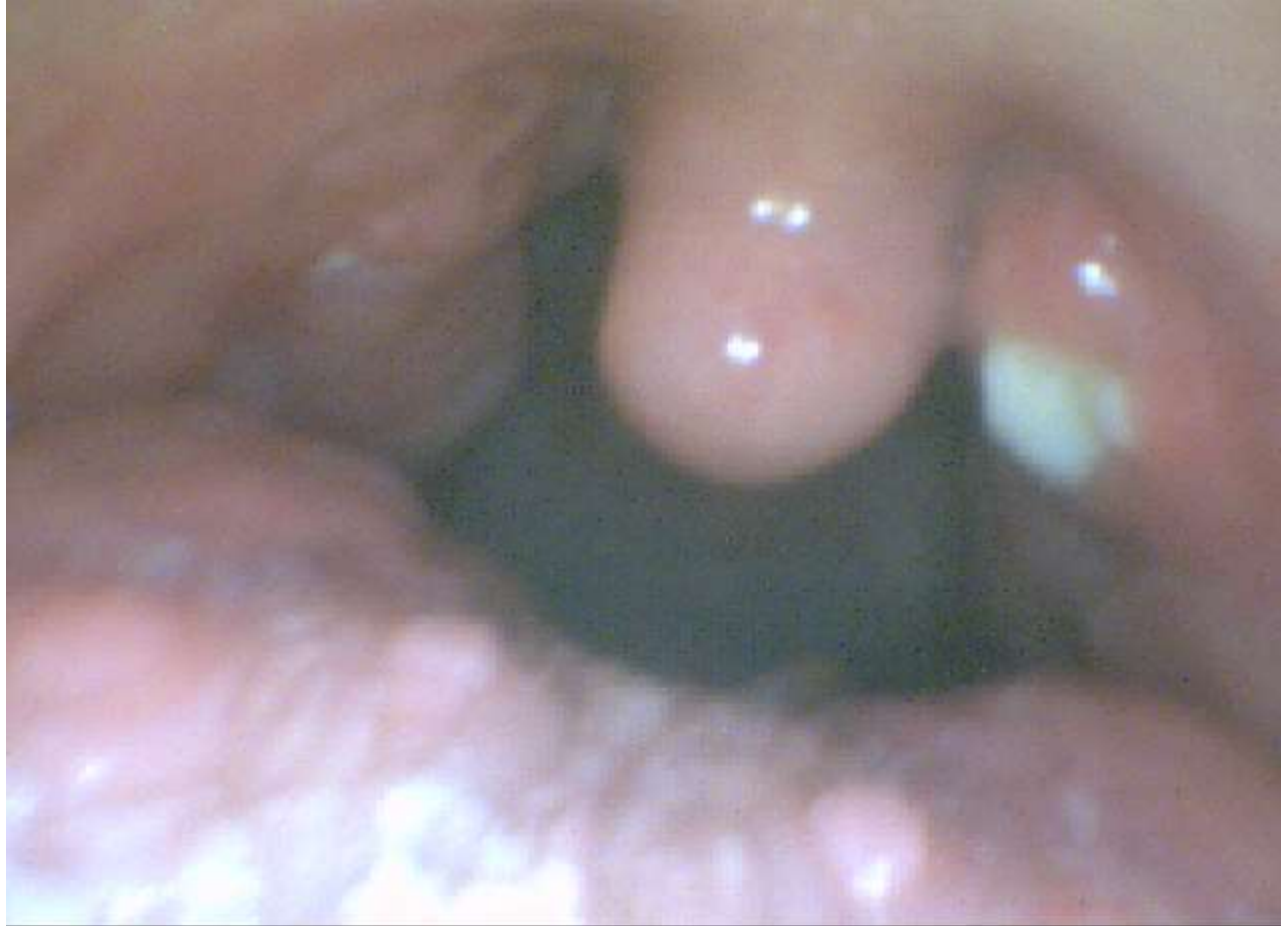

March 6 - May 16, 2009

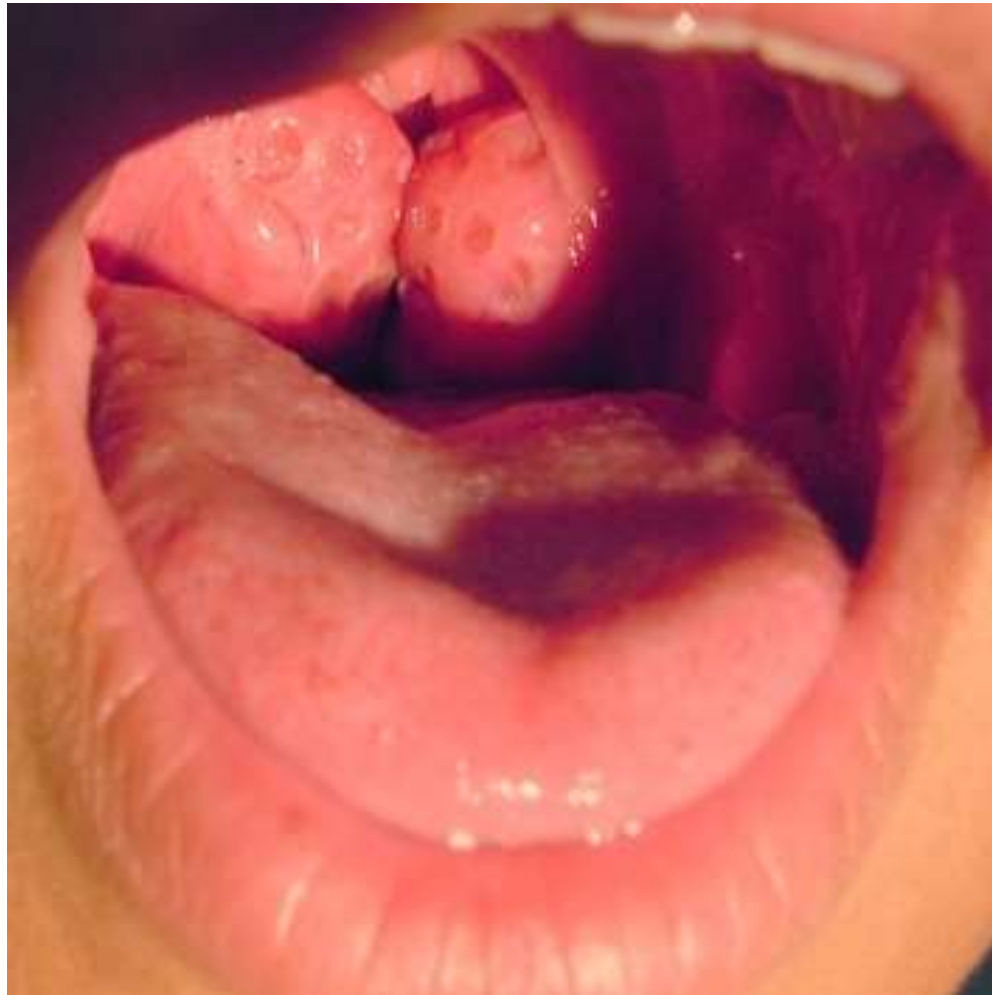Oroscopia



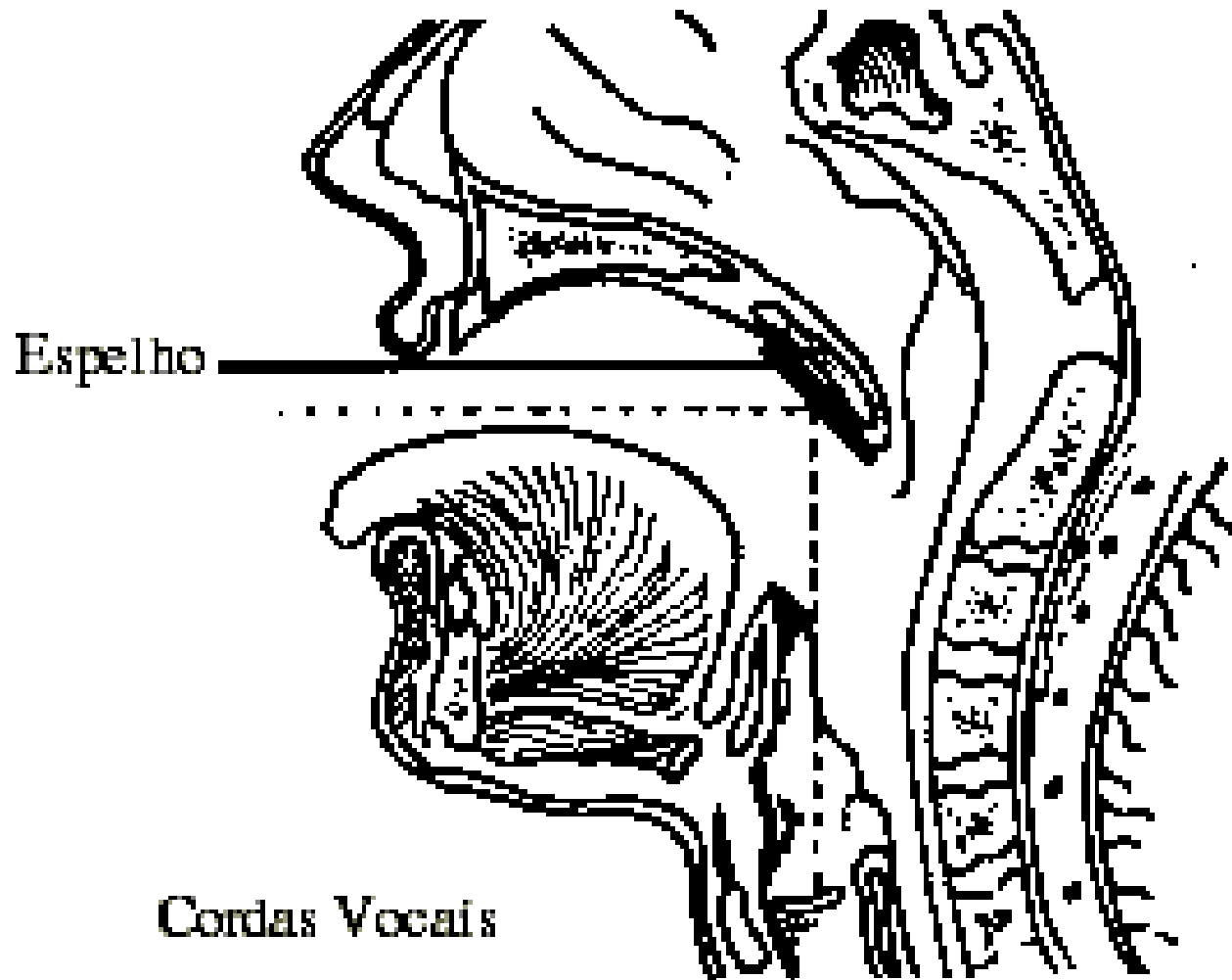
Oroscopia



Oroscopia



Laringoscopia



Laringoscopia



